

# Computed Tomography for Diagnosis and Therapeutic Planning of Nasopalatine Duct Cyst Clinical Case Report

*Tomografia Computadorizada para Diagnóstico e Plano de Tratamento  
do Cisto do Ducto Nasopalatino  
Relato de Caso*

*Tomografía Computarizada de Diagnóstico y Planificación Terapéutica  
de Quiste del Conducto Nasopalatino  
Reporte*

Pietry Dy Tarso Inã Alves **MALAQUIAS**<sup>1</sup>

Marcelo Victor Omena Caldas **COSTA**<sup>1</sup>

Igor Lerner Hora **RIBEIRO**<sup>1</sup>

Anaclécia dos Santos **BATISTA**<sup>2</sup>

Viviane Almeida **SARMENTO**<sup>3</sup>

Rodrigo Tavares **BOMFIM**<sup>1</sup>

<sup>1</sup> *Departamento de Cirurgia Bucomaxilofacial, Faculdade de Odontologia, Hospital Santo Antônio “Obras Sociais Irmã Dulce”  
Universidade Federal da Bahia, Salvador, Bahia, Brasil.*

<sup>2</sup> *Faculdade de Odontologia, Universidade Federal da Bahia, Salvador, Bahia, Brasil.*

<sup>3</sup> *Departamento de Radiologia, Faculdade de Odontologia, Universidade Federal da Bahia, Salvador, Bahia, Brasil.*

The nasopalatine duct cyst (NPDC) is a non-odontogenic cyst that occurs in the anterior maxillary region. It's generally painless and diagnosed through conventional radiographic examination. Enucleation is usually the surgical procedure chosen for this type lesion, but when untreated, it can reach large dimensions and require surgical procedures in hospitals. Imaging exams are fundamental to determine the extent of the injury and adjacent tissue involvement, and thus better tailor treatment for each case. Because of anatomical overlapping in some cases, conventional radiographs are not sufficient to assess tissue depth. However, by using different tools and reconstructions, computed tomography (CT) allows accurate bone and soft tissue lesion assessment, which makes it essential in many situations in dentistry. This study aims at reporting the case of a large NPDC, in which CT was vital for diagnosing and planning surgical enucleation.

**Keywords:** Nasopalatine Duct Cyst, Cone beam CT, Jaw Cysts.

## INTRODUCTION

Because of its high sensitivity and specificity, Computed Tomography (CT) is an imaging modality that is often used as support to diagnoses. This type of examination allows reconstructing images of a particular anatomic segment from several angles and in different ways, accurately identifying pathologies, their

limitations, characteristics and relations to adjacent tissues. CT also allows visualizing and assessing soft tissues and mineralized structures, as well as estimating distances, areas, volume and tissue attenuation coefficient, all of these with high quality images, fast performance and low-dose ionizing

radiation. Thus, this type of examination has become an excellent tool for diagnosis and therapeutic planning in several fields of health care<sup>1-3</sup>.

Nasopalatine Duct Cyst (NPDC) is a non-odontogenic cyst that represents about 1 to 11.6% of maxillary cysts. It develops in the oral cavity, particularly in the hard palate, and it usually determines the protrusion in the nasal vestibule. Its origin derives from epithelial embryonic cells in the nasopalatine duct. The type of lesion is painless and not bigger than 20mm in diameter. It is usually diagnosed through conventional radiographic examination. In case of large lesions, which may determine noticeable facial disfigurement, CT is elected the best examination for analyzing lesion size, limits and relation with the noble structures involved<sup>4-9</sup>.

The objective of this study is report a clinical case of large-sized NPDC, in which CT was essential for diagnosis and surgical treatment planning.

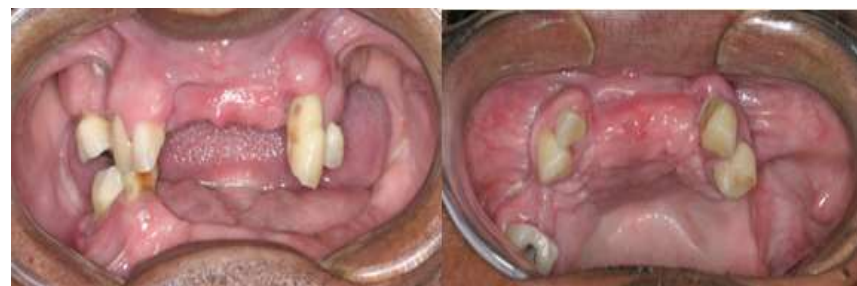## CASE REPORT

Patient C.A.O, 56 years old, male, dark-skinned, single, self-employed, born in Salvador, Bahia, Brazil, looked for the School of Dentistry at Federal University of Bahia (UFBA) on August 6, 2007, saying "I've lost my teeth and would like to have a prosthesis". During anamnesis interview, patient reported having pharmacologically controlled hypertension (130/80mmHg) and denied having allergies or other systemic problems. He also reported brushing his teeth three times a day, drinking alcohol moderately, and not smoking.

During extraoral examination, a painless slight increase in volume in the maxillary anterior area was noticed. Upon palpation, it showed fluctuation and depressibility.

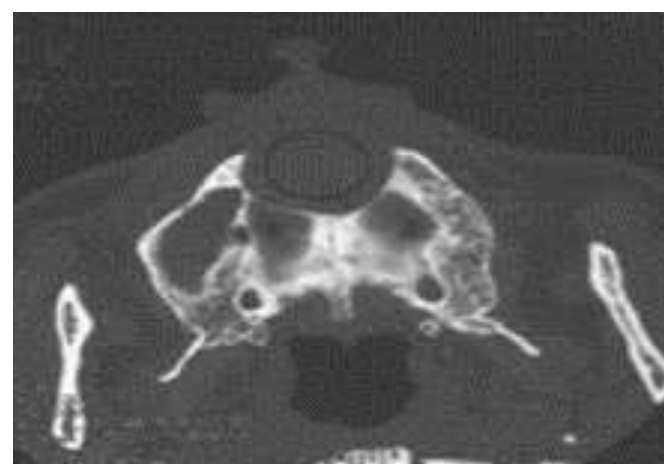During intraoral examination, besides many missing teeth and periodontal disease, an increase in volume in the anterior hard palate region was also noticed (Figure 1 /A, B). Periapical, upper occlusal and

panoramic radiography was requested. It showed large radiolucent area on the middle maxillary line.

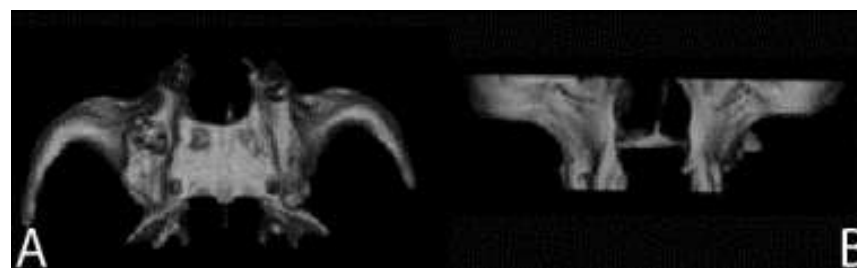


**Figure 1 (A, B).** Absence of teeth and gingival recession (A). Increased volume in the hard palate in the anterior maxillary region (B)

However, because of its anatomical overlapping, the exact boundaries of the lesion and possible involvement of nasal cavities were not totally clear. Thus, a CT exam of the maxilla was requested. Two-dimensional axial, coronal and sagittal sections and three-dimensional reconstruction showed the lesion extension to nasal cavity and resorption of nasal septum. The largest dimensions of the lesion could be assessed, as well as its attenuation coefficient (10.7 UH), which showed high-protein liquid content, compatible to cystic liquid (Figures 2, 3/A, B).



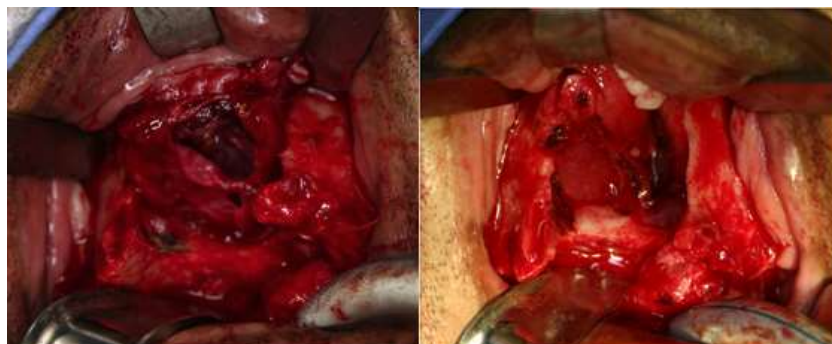
**Figure 2.** CT axial section, in which coefficient of pathologic area is being checked



**Figure 3 (A, B).** Three-dimensional reconstruction of the same case, showing extension of lesion and nasal cavity compromising

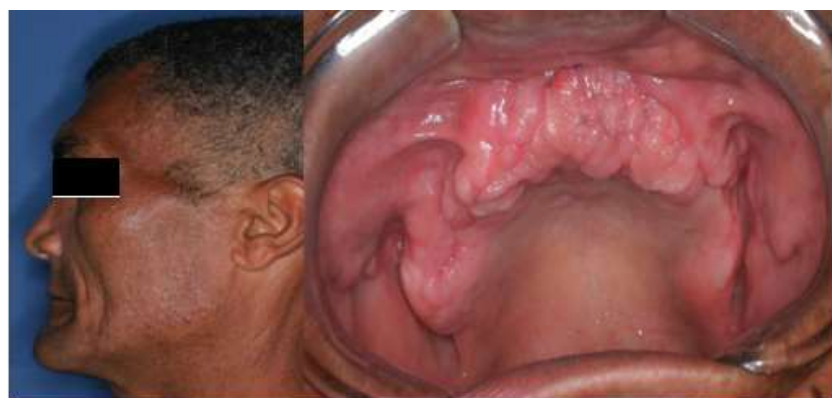Based on the data obtained from clinical and imaging examination, the diagnosis hypothesis was NPDC. Due to lesion dimensions and involvement of

adjacent tissues, a surgical enucleation under general anesthesia was scheduled in hospital environment. December 5<sup>th</sup>, 2007, surgical enucleation of hard palate lesion was carried out at the University Hospital – UFBA (Figure 4/A, B).



**Figure 4 (A, B).** Trans-surgical. (A)- After opening flap, exposing cystic lesion. (B)- After removing lesion, nasal cavity can be seen

The surgical specimen was placed in a flask containing formaldehyde at 10% and sent for anatomical-pathological examination at the Pathologic Anatomy Laboratory at the School of Dentistry at UFBA, together with the biopsy records and complementary exams. Antibiotics, anti-inflammatory and analgesic were prescribed. There were no complications during post-surgery period (Figure 5).



**Figure 5 (A, B).** Postsurgery. (A)- Profile and (B) – intraoral photo of patient after surgery, in which increased maxilla volume can no longer be noticed

Histological biopsy report confirmed the NPDC hypothesis. Macroscopic sections showed four dark brown soft tissue fragments in formaldehyde, with irregular surfaces and shapes and measuring together 5 x 3 x 1.5cm. Microscopic sections showed cystic fibrous wall covered by simple cuboidal epithelium, as well as by respiratory epithelium and sinus mucosa with moderate chronic inflammatory infiltrate. Patient was forwarded to prosthetic rehabilitation. After 5 years, there have been no signs of relapse.

## DISCUSSION AND CONCLUSION

The anterior maxillary region has high incidence of cysts and tumors. Among these, dentigerous and radicular odontogenic cysts are the most frequent. And among the non-odontogenic cysts, the most frequent one is NPDC, which corresponds to about 11.6% of all maxillary cysts<sup>10-13</sup>. Nonaka et al.<sup>14</sup> assessed 10,311 biopsy tests of the oral and maxillofacial region between 1970 and 2009 and verified that the most frequent non-odontogenic cyst were lymphoepithelial cyst, corresponding to 17.2%; epidermoid cyst, 20.7%, and NPDC, 32.8% of the total. Therefore, these three types of cyst correspond to about 70.7% of all non-odontogenic cysts.

NPDC's origin is uncertain, despite all the hypotheses made about its etiology, such as remains of epithelial embryonic cells of the nasopalatine canal. Occurs predominantly among males, in a proportion of 2.5:1, individuals in their thirties are most subject to NPDC, but it has also been diagnosed among individuals in their fourth, fifth and sixth decade of life. Ethnicity is not associated to NPDC. Lesions are often located in the hard palate, close to the incisive foramen in the nasopalatine canal. It can determine vaulting in the region, nasolabial protrusion, and side expansion in the maxilla<sup>4,8,11,13</sup>. NPDC is painless and slow-growing, and it can involve cortical bones and cause facial disfigurement, according to the present case<sup>8</sup>.

Thus, the importance of correct diagnosis in order to carry out treatment effectively. There are other pathologies or anatomical alterations associated to the same place that may have their diagnoses confused, which require different procedures. Imaging and histopathological examination, associated to clinical exam, are essential to confirm diagnosis<sup>10-13</sup>.

In imaging examination, NPDC is presented as a radiolucent with a well-defined oval or circular area circumscribed by radiopaque halo, close to or on the middle line of anterior maxillary region, between the

apices of upper central incisive teeth. This radiolucent area may show itself shaped like a “heart” because of the anterior nasal spine image overlapping. The cyst usually measures from 1 to 2.5 cm and it rarely causes radicular resorption<sup>15</sup>.

It is difficult to differ between an increased nasopalatine duct and a small NPDC, 6mm are considered the boundary limit between them. High definition imaging examinations such as CT are very useful to help diagnosis, because of their quality, high sensitivity and specificity. They provide us with the means to reconstruct images; assess different angles; accurately identify the pathology and their limits toward adjacent tissues; as well as suggest intralesional content based on linear lesion attenuation coefficient, which was important to assess the extensive lesion and associated structures in the present case<sup>1-3</sup>.

Diagnosis of radiolucent areas in the anterior maxillary region should be carried out so as to decide the best treatment<sup>5</sup>. For lesions in which endodontic origin is suspected, pulp sensitivity testing needs to be performed. Besides tooth examination and radiographs, histopathology is considered to be mandatory for a differentiated diagnosis.

Histologically, NPDC shows a cystic capsule made up of thick connective tissue, covered by stratified scaly epithelium of simple cubic epithelium. Mononuclear inflammatory infiltrate can also be observed. The cystic wall component can directly influence cystic liquid characteristics. Cystic fluid can be made of serous component or even keratin<sup>8,15,16</sup>.

Enucleation is usually the surgical procedure chosen for this type lesion because of its low relapse rate. For large lesions, marsupialization can be considered so as to avoid oroantral fistulas. Some authors report good results using this technique<sup>8</sup>.

However, there is no standardized lesion size or specific radiographic findings that indicate this technique. Post-surgical supervision is important in order to avoid complications and to allow oral rehabilitation<sup>8,9,13</sup>.

Correctly evaluating lesion size, limits and associated anatomic structures provides the surgeon with conditions to decide on the surgical technique and surgical intervention environment<sup>8</sup>. In the case reported here, surgical enucleation in hospital environment was chosen because of lesion size and association to adjacent structures. This enabled higher hemostatic control and more comfort to patient. Some reported complications after surgery are paresthesia, fistula, hemorrhage, pain, edema, neuralgia, and drainage of purulent matter<sup>4</sup>, but none of these complications were observed.

#### RESUMO

*O Cisto do Ducto Nasopalatino (CDN) é um cisto não odontogênico que acomete a região anterior da maxila. Quando não tratado pode atingir grandes dimensões exigindo uma abordagem cirúrgica em nível hospitalar. Os exames de imagem são fundamentais para determinar a extensão da lesão e comprometimento dos tecidos vizinhos, e desta forma melhor planejar o tratamento de cada caso. As radiografias convencionais, devido à sobreposição anatômica e por não permitir avaliar a profundidade dos tecidos, torna-se insuficiente nesses casos. A tomografia computadorizada, entretanto, por meio de diferentes reconstruções e ferramentas, permite avaliar precisamente lesões ósseas e em tecido moles, tornando-se imprescindível em muitas situações na Odontologia. O objetivo deste trabalho é relatar um caso clínico de CDN de grandes proporções, no qual a TC foi de fundamental importância para o diagnóstico e planejamento de sua enucleação cirúrgica.*

**Palavras Chave:** Cisto do Ducto Nasopalatino, Tomografia Computadorizada, Cistos Maxilomandibulares.

#### RESUMEN

*El quiste del conducto nasopalatino (CDNP) es un quiste no odontogénico que se produce en la parte anterior del maxilar. Es indoloro y generalmente se diagnostica mediante un examen radiográfico convencional. La enucleación es el procedimiento quirúrgico por lo general elegido para este tipo de lesiones, pero cuando se deja sin tratamiento, puede lograr grandes y requieren procedimientos quirúrgicos en los hospitales. Los estudios de imagen son esenciales para determinar la extensión de la implicación tejido de la lesión y tratamiento adyacente y por lo tanto adaptar mejor para cada caso. Debido a la superposición anatómicas, en algunos casos, las radiografías*

no son suficientes para evaluar la profundidad de la tela. Sin embargo, el uso de diferentes herramientas y reconstrucciones, tomografía computarizada (TC) permite la evaluación precisa de la lesión de hueso y tejidos blandos, que es esencial en muchas situaciones en odontología. Este artículo tiene como objetivo informar sobre el caso de una gran CDNP, donde CT Ffoi fundamental para el diagnóstico y la planificación de la enucleación quirúrgica.

**Palabras clave:** *Quiste Del Conducto Nasopalatino, Tomografía, Quistes Maxilomandibulares.*

## REFERENCES

1. Perrella A, Borsatti MA, Rocha RG, Cavalcanti MGP. Validation of computed tomography protocols for simulated mandíbula lesions. A comparison study. *Braz Oral Res.* 2007; 21(2): 165-9.
2. Albuquerque MAP, Kuruoshi ME, Oliveira IRS, Cavalcanti MGP. CT assessment of the correlation between clinical examination and bone involvement in oral malignant tumors. *Braz Oral Res.* 2009; 23(2): 196-202.
3. Suter VG, Sendi P, Reichart PA, Bornstein MM. Nasopalatine Duct cyst: an analysis of the relation between clinical symptoms, cyst dimensions, and involvement of neighboring anatomical structures using cone beam computed tomography. *J Oral Maxillofac Surg.* 2011; 69(10):2595-603
4. Yoshiura K, Higushi Y, Kazuyuki A, Shinohara M. Morphologic analysis of odontogenic cysts with computed tomography. *Oral Surg Oral Med Oral Pathol Oral Radiol Endod.* 1997; 83(6): 712-8.
5. Faitaroni LA, Bueno MR, Carvalhosa AA, Mendonça EF, Estrela C. Differential diagnosis of apical periodontitis and nasopalatine duct cyst. *J Endod.* 2011; 37(3): 403-10. doi: 10.1016/.
6. Sumer AP, Celenk P, Sumer M, Telcioglu NT. Nasolabial cyst: case report with CT and MRI findings. *Oral Surg Oral Med Oral Pathol Oral Radiol Endod.* 2010; 109(2): 92-4. doi: 10.1016/
7. Aquilino RNA, Bazzo VJ, Faria RJA, Leocádia N. Nasolabial Cyst: presentation of a clinical case with CT and MPR images. *Braz J Otorhinolaryngol.* 2008; 74(3): 467-71.
8. Tanaka S, Lida S, Murakami S. Extensive nasopalatine duct cyst causing nasolabial protusion. *Oral Surg Oral Med Oral Pathol Oral Radiol Endod.* 2008; 106:46-50.
9. Bondner L, Woldenberg Y, Bar-Zir J. Radiographic freatures of large cystic lesions of the jaws in children. *Pediatr Radiol.* 2003; 33: 3-6.
10. Ortega A, FarinãV, Gallardo A, Espinoza I. Nonendodonticperiapical lesions: a retrospective study in Chile. *Int Endod J.* 2007; 40: 386-90.
11. Cicciú M, Grossi G B, Borgonovo A, Santoro G. Raro bilateral nasopalatine duct cysts: a case report. *Open Dent J.* 2010; 4: 8-12.
12. Grossmann SM, Machado VC. Demographic profile of odontogenic and selected nonodontogenic cysts in a Brazilian population. *Oral Surg Oral Med Oral Pathol Oral Radiol Endod.* 2007; 104: 35-41.
13. Torres LM, Benito JI, Morais D, Fernández A. Nasopalatine duct cyst: case report. *Acta Otorrinolaringol Esp.* 2008; 59(5): 250-1.
14. Nonaka CFW, Henriques ACG, Matos FR, Souza LB. Nonodontogenic cysts of the oral and maxillofacial region: demographic profile in a Brazilian population over a 40-year period. *Eur Arch Otorhinolaringol.* 2011; 268: 917-22.
15. Neville BW, Damm DD, Allen CM, Bouquot JE. *Patologia oral e maxilofacial.* 2 ed. Rio de Janeiro: Guanabara Kogan; 2004.
16. Cavalcanti MGP, Santos DK, Perrella A, Vannier MW. CT – based analysis of malignant tumor volume and localization. A preliminary study. *Braz Oral Res.* 2004;18(4): 338-44.

### Correspondência

**Pietry Dy Tarso Inã Alves Malaquias**  
Faculdade de Odontologia, UFBA  
pietrymalaquias@hotmail.com

Received: August 18, 2013

Accepted: October 14, 2013