

Semidirect vital tooth onlay restoration: a case report

Restauração semidireta onlay em dente vital: caso clínico

Restauración semidirecta de onlay de dientes vitales: reporte de caso

Rodrigo Barros Esteves **LINS**

Marina Rodrigues **SANTI**

Luís Roberto Marcondes **MARTINS**

Department of Restorative Dentistry, Piracicaba Dental School, University of Campinas, Avenida Limeira, 901, Bairro Areião, Piracicaba 13414-903, SP, Brazil

Abstract

In the loss of much of the coronary structure, either through caries or a fracture, it is indicated to perform restorative laboratory techniques in order to re-establish the patient's health, function and aesthetics, through conservative and minimally invasive techniques. The aim of this manuscript was to report on a clinical case of a posterior restoration using a semidirect resin composite onlay restoration. Initially, a direct morphological reconstruction of bulk-fill resin was performed, followed by cavity preparation with diamond tips. Alginate molding and a model of elastomer-based material were performed. The professional made the onlay piece in micro-hybrid resin composite in the model incrementally. Cementation was performed with dual resin cement following manufacturer's recommendations. Finally, the occlusal adjustment was performed in the maximum habitual intercuspal position and during eccentric mandible movements. It might be concluded that the semidirect restorative technique in resin composite is as effective as direct and indirect restorations; however, the correct indication of these restorative procedures will define the clinical prognosis.

Descriptors: Dental Restoration; Permanent; Molar. Rehabilitation.

Resumo

A perda de grande parte da estrutura coronária, seja por cárie ou fratura, indica-se a realização de técnicas restauradoras laboratoriais, a fim de reestabelecer a saúde, função e estética ao paciente, através de técnicas conservadoras e minimamente invasivas. O objetivo deste artigo científico foi relatar um caso clínico de restauração posterior através de uma restauração semidireta onlay em resina composta. Inicialmente, foi realizado uma reconstrução morfológica em resina composta bulk fill de forma direta, seguido do preparo da cavidade com pontas diamantadas. Foi realizado a moldagem com alginato e o molde a partir de material a base de elastômeros. O próprio profissional confeccionou a peça onlay em resina composta microhíbrida no modelo de forma incremental. Para a cimentação, foi realizada a cimentação com cimento resinoso dual, seguindo recomendações do fabricante. Para finalizar, foi realizado o ajuste oclusal em máxima intercuspidação habitual e durante movimentos excêntricos da mandíbula. Pode-se concluir que a técnica restauradora semidireta em resina composta é tão eficaz quanto a restauração direta e indireta, contudo, a correta indicação destes procedimentos restauradores definirão o prognóstico clínico.

Descritores: Restauração Dentária Permanente; Dente Molar; Reabilitação.

Resumen

La pérdida de gran parte de la estructura coronaria, ya sea por caries o fractura, está indicada para realizar técnicas de restauración de laboratorio con el fin de restaurar la salud, la función y la estética del paciente a través de técnicas conservadoras y mínimamente invasivas. El objetivo de este trabajo científico fue informar un informe de un caso de restauración posterior a través de una restauración de recubrimiento de resina compuesta semi-directa. Inicialmente, se realizó una reconstrucción morfológica directa de la resina de relleno a granel, seguida de la preparación de la cavidad con puntas de diamante. Se realizaron moldes de alginato y moldeo de material a base de elastómero. El profesional mismo hizo la pieza onlay en resina compuesta micro-híbrida en el modelo de forma incremental. Para la cementación, la cementación se realizó con cemento de resina dual, siguiendo las recomendaciones del fabricante. Finalmente, el ajuste oclusal se realizó en la posición intercuspal habitual máxima y durante los movimientos excéntricos de la mandíbula. Concluimos que la técnica de restauración semi-directa en resina compuesta es tan efectiva como la restauración directa e indirecta, sin embargo, la indicación correcta de estos procedimientos de restauración definirá el pronóstico clínico.

Descriptores: Restauración Dental Permanente; Diente molar; Resinas Compuestas; Polimerización.

INTRODUCTION

The partial loss of the coronary structure, either through caries or a fracture, and depending on the amount of dental remnant present, an indirect restoration is indicated, which can be classified into inlays, onlays, overlays or even an endocrown and a full crown; with less involvement of the dental structure and with greater involvement of the cusps, respectively.¹ These procedures today are solely focused on adhesive dentistry, based on minimally invasive techniques^{1,2}.

Direct restoration in resin composite is still the procedure of choice for restorations and is commonly present in the dental clinic. Therefore, indirect techniques have emerged as alternative, making the restorative procedure free of problems arising from the handling of resin composite directly into the cavity, especially in large cavities such as occlusal and proximal contact control, as well as marginal disadaptation³. Other problems or limitations are related to polymerization shrinkage and stresses inherently caused by resin composite^{4,5}, causing marginal gap formation and, consequently,

susceptibility to marginal infiltration and secondary caries formation⁶⁻⁸. One way to reverse or control this limitation is by cementing pieces of resin composite or ceramic material in onlay restorations, making the polymerization shrinkage limited to the thin layer of the resin cement⁹.

These resin cements are considered the material of choice for cementing laboratory parts, whether composite or ceramic, in relation to zinc phosphate, glass ionomer and low viscosity composite cements¹⁰. Resin cements have the property of bonding with dental, enamel and dentine tissues and the laboratory part, protecting dentine exposure as well as exceptional mechanical properties such as high tensile and compressive strengths¹¹. Dual resin cement, which has a polymerization process by chemical reaction and light activation, is usually used in cementation in indirect restorations and studies indicate a careful performance in the photoactivation process after the restorative to prevent stress build-up from the resin polymerization process⁸.

The semidirect technique is a procedure in which the professional develops the laboratory work in resin composite from a partial or total moulding of the cavity to be restored, making the restorative procedure faster, with a lower cost and meeting the functional and aesthetic criteria of the indirect restorative procedure, restoring oral/occlusal health¹². The aim of this clinical case was to report a posterior restoration of a resin composite onlay through a semidirect technique.

CLINICAL CASE

A 28 years-old woman sought dental care at the Postgraduate Clinical of the Piracicaba Dental School of the University of Campinas. Anamnesis, medical and dental records were performed, as well as clinical assessment and diagnosis. The patient complained of a "fractured tooth" and that she "did not have a beautiful smile". No systemic disease was reported during the medical history, besides not being under medical treatment, not using any medication and not having any allergies. The patient's dental history consisted of orthodontic treatment between 15 and 18 years of age, and between 21 and 26 years of age, in addition, she had eight teeth extraction (15, 18, 25, 28, 35, 38, 44 and 45), by orthodontic indication. During the clinical examination, no changes in the oral mucosa and surrounding tissues were observed. The odontogram indicating unsatisfactory resin composite restorations on teeth: 22 (over content and lack of aesthetics, Class III mesial), 36 (lack of aesthetics, over contour, marginal pigmentation and irregular proximal contact, Atypical Class (mesio-occlusal-distal) and 46 (marginal fracture, Class II mesio-occlusal-distal); besides this, the patient had an inharmonious gingival contour and pigmentation in all teeth (Figure 1).

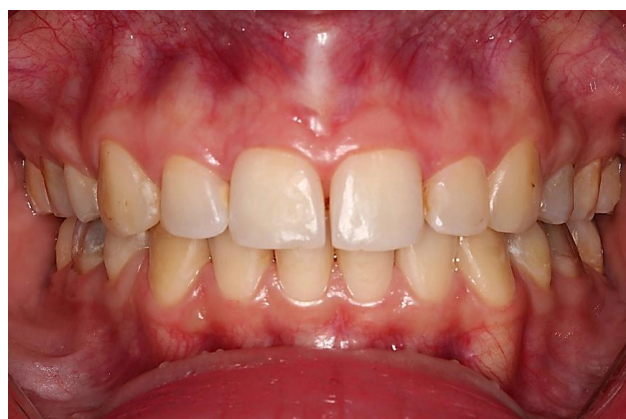

Figure 1: Initial aspect of buccal surface teeth.

Initially, initial periodontal treatment was proposed in order to control the biofilm by removing retention factors such as restoration and polishing of the restorations and removal of the supra-gingival calculus through periodontal cures and ultrasound, as well as reinforcement of oral hygiene instructions. As a second step, periodontal surgery (gingivoplasty)

involving teeth 12 to 23 was planned and performed in order to re-establish gingival harmony between the superior anterior teeth, defining the better gingival zenith. As a third step, dental bleaching was performed by bleaching with 35% hydrogen peroxide (Whitess HP, FGM, Joinville, SC, Brazil), using a dental office technique. Three sessions were performed at one-week intervals, and each session was applied three times, the whitening gel was applied on the enamel surface for a time of 15 minutes each. The last and main step of this case report was the indirect composite onlay on tooth 36 (lower left first molar): Previously, this dental tooth had an atypical resin composite (mesio occlusal distal buccal) restoration that had been fractured (Figure 2). The entire restoration was removed, and morphological reconstruction with bulk-fill resin composite was performed (Figure 3). Subsequently, the patient returned to continue the restorative treatment by means of a resin composite onlay.

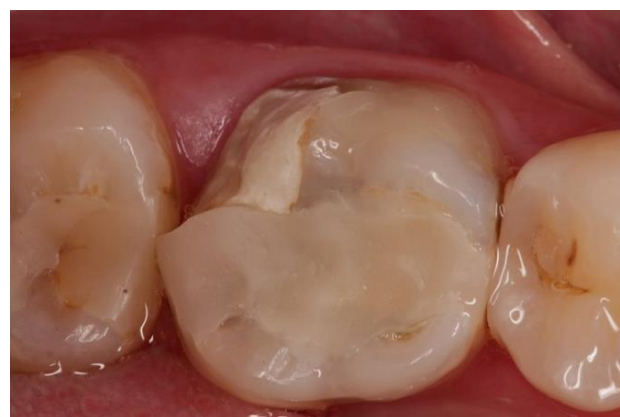

Figure 2: Initial aspect of tooth fracture.

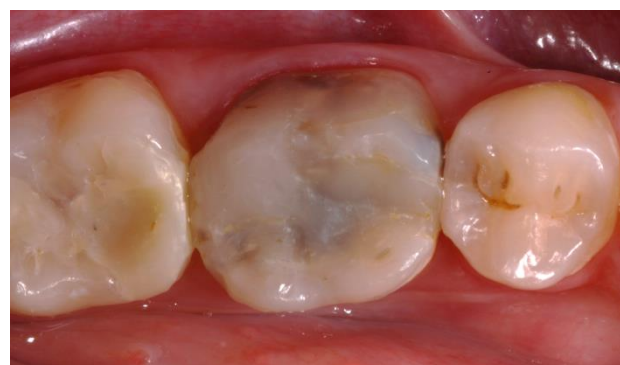

Figure 3: Restoration with bulk-fill composite.

The morphological reconstruction was lacking an adequate contact point and was very pigmented, due to the darkened colour of the dental remnant, it is important to note that this tooth was vital, so a conservative approach through adhesive techniques was chosen.

The preparation for an onlay was performed, involving the mesial, occlusal, distal and buccal surfaces of the tooth. Then, we proceeded with supragingival bevel vestibular wear with a diamond-tipped round-tipped conical trunk (4138) (KG Sorensen, Cotia, SP, Brazil); occlusal wear and

proximal boxes with a rounded tapered diamond tip (3131) (KG Sorensen, Cotia, SP, Brazil); interproximal wear, in order to perform the dental separation with thin tapered trunk diamond tips (2200) (KG Sorensen, Cotia, SP, Brazil), with protection of metal strips in the proximal region; reduction of the cusps with rounded end tapered trunk diaphragm tip (4138) and finishing of all the walls with a multi-laminated drill bit 7664 (Komet Dental, Lemgo, Germany) (Figure 4).

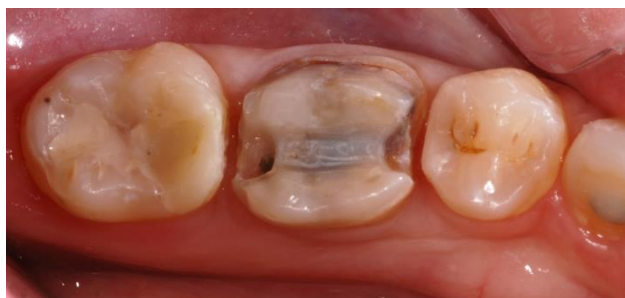

Figure 4: Preparation for onlay restoration.

All the characteristics of the preparation for an onlay were evaluated, such as expulsion of all walls to the occlusal, rounded internal cavity angles, a rounded cavosurface angle; separation of the adjacent teeth, supragingival marginal end, adequate occlusal height in centric relation and proximal boxes with inferior wear in relation to the occlusal box was then performed with moulding in a partial mould alginate (Hydrogum, Zhermack, Badia Polesine, RO, Italy) and the cast model with silicone material (VOCO, Cuxhaven GmbH, Germany). In the silicone model (Figure 5), the resin composite was inserted, being more opaque to the restoration body and more translucent to the enamel, returning the entire anatomy of the tooth 36.

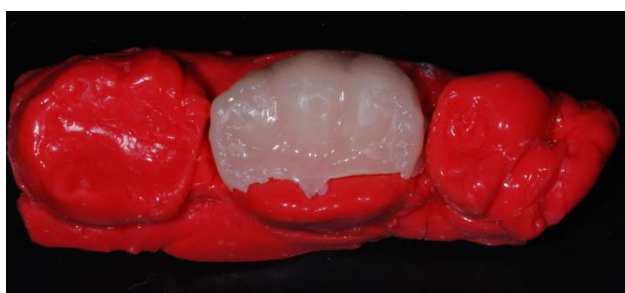


Figure 5: Semidirect onlay restoration.

All the increments inserted were light-cured for 40 seconds. (VALO Cordless, Ultradent, South Jordan, UT, USA). The resin composite piece was adjusted in the mouth by means of diamond tips with anatomy compatible with the desired region, and after the adjustments, the part was cemented. Initially, 35% phosphoric acid was applied to the inside of the part, washed, dried, silane applied and awaiting its evaporation; Selective acid etching was performed on the enamel for at least 30 seconds, washed and dried, and the Futurabond U universal adhesive (VOCO, Cuxhaven GmbH, Germany) applied, volatilized and light cured for 10 seconds. The dual resin cement

chosen was Bifix QM (VOCO, Cuxhaven GmbH, Germany). This resin cement was inserted directly into the inner face of the piece and seated in preparation; all excess was removed and still under digital pressure light curing was continued for 40 seconds on each face. To complete the restorative procedure (Figure 6), the occlusal adjustment was performed at the maximal intercuspal position and during jaw occlusion (laterality and protrusion) with rounded diamond tips. The edges of the restoration were finished with diamond tips F and FF, as well as the entire polishing protocol: high and low granulation abrasive rubbers for resin composite, felt abrasive disk pastes and finishing with silicon carbide brushes.

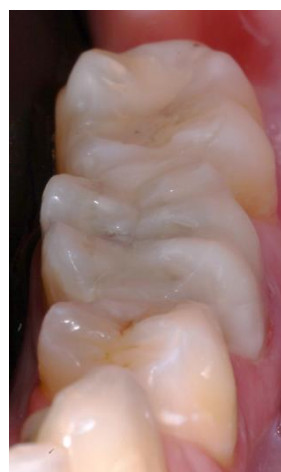

Figure 6: Final aspect of onlay restoration.

DISCUSSION

The choice of restorative material, restorative technique and adhesive system are important points that should be taken into consideration based on each individual clinical case. In the present case report, a semidirect composite onlay restoration was performed on the lower left first molar, which showed no adequate proximal contact point, lack of anatomy, as well as a transparency of the colour of the vital dental remnant.

The use of a direct resin composite is unquestionably prevalent in the clinical routine, and with the emergence of bulk-fill resin, this predilection has grown even more⁸; however, a better understanding of the professional in the correct clinical and technical indications of this material is necessary¹³, because it presents monomeric changes that directly influence the clinical behaviour, as demonstrated in the clinical case. Tooth 36 had a morphological reconstruction with bulk-fill resin composite, which could not mask or minimise the colour of the reaction substrate, nor was it able to return the correct shape of the tooth by involving a large amount of lost structure, compromising the occlusion of the patient, and did not re-establish the interproximal contact properly, causing proximal food impaction, which could lead to periodontal complications. In summary, all important and

essential points that should be re-established in a restoration, whether direct, semidirect or indirect, such as function, health and aesthetics, were not performed correctly, so the indication of a semidirect composite onlay restoration was the most appropriate³.

The semidirect resin composite restoration was chosen for this clinical case, since the patient did not have sufficient financial conditions for a ceramic laboratory work, besides her desire to perform the resin composite restoration, on the other hand, we can list some favourable factors in performing a resin composite restoration in place of ceramic, such as a lower hardness, avoiding adjacent tooth wear by constant occlusal contact; the time for making the piece is shorter and can be done by the professional himself in a clinical setting; the cost is lower, easier to wear during occlusal adjustment, as well as a simpler polishing technique^{14,15}.

In a systematic review with a meta-analysis by Morimoto et al.², observed that the failure rate of indirect restorations in vital teeth was significantly lower compared to endodontically treated teeth, which makes the indication of performing an onlay semidirect restoration in this clinical case with an excellent clinical prognosis, since the tooth 36 was vital.

For the cementation of the resin composite part, resin cement Bifix QM was used, which presents as a characteristic of the dual polymerization process, through a chemical reaction and light. Soares et al.⁸ argue that it is necessary to wait a period after the cementation of the part with the resin cement, to start the photoactivation, since this way a decrease of the polymerization shrinkage occurs and, consequently, a correct polymerization of the material is necessary achieved. This form of polymerization of the material mainly decreases the pulp wall polymerization shrinkage, thus avoiding postoperative sensitivity⁸. Furthermore, clinical studies in the scientific literature show that the longevity of the indirect restorations cemented with this type of resin cement compared to self-adhesive are not significantly different¹⁶.

In order to provide better bond strength between the resin cement and the dental structure, it was recommended during the preparation the exposure of the enamel margin, also reaching areas of dentine, specifically in the marginal end region, as well as in the proximal boxes since the fracture resistance of an indirect restoration is favoured due to the better distribution of the force vectors, that is, the biomechanical behaviour of the restoration¹⁷. Polymerization shrinkage is also a factor to be considered in this situation, as resin cement will promote a smaller marginal gap, leading to lower susceptibility to marginal microleakage when compared to directly inserted resin composite¹⁸.

CONCLUSION

It can be concluded from this clinical case and the literature review that semidirect resin composite restoration is as effective as direct restoration; however, the correct indication of these restorative procedures will define the clinical prognosis.

REFERENCES

1. Angeletaki F, Gkogkos A, Papazoglou E, Kloukos D. Direct versus indirect inlay/onlay composite restorations in posterior teeth. A systematic review and meta-analysis. *J Dent.* 2016;53:12-21.
2. Morimoto S, Rebello de Sampaio FB, Braga MM, Sesma N, Özcan M. Survival rate of resin and ceramic inlays, onlays, and overlays: a systematic review and meta-analysis. *J Dent Res.* 2016;95(9):985-94.
3. Spreafico RC, Krejci I, Dietschi D. Clinical performance and marginal adaptation of class II direct and semidirect composite restorations over 3.5 years in vivo. *J Dent.* 2005;33(6):499-507.
4. Lins R, Vinagre A, Alberto N, Domingues MF, Messias A, Martins LR et al. Polymerization Shrinkage Evaluation of Restorative Resin-Based Composites Using Fiber Bragg Grating Sensors. *Polymers (Basel).* 2019;11(5):859.
5. Lins RBE, Aristilde S, Osório JH, Cordeiro CMB, Yanikian CRF, Bicalho AA et al. Biomechanical behaviour of bulk-fill resin composites in class II restorations. *J Mech Behav Biomed Mater.* 2019;98:255-61.
6. Opdam NJ, Roeters FJ, Feilzer AJ, Verdonchot EH. Marginal integrity and postoperative sensitivity in Class 2 resin composite restorations in vivo. *J Dent.* 1998;26(7):555-62.
7. Bicalho AA, Valdívia AD, Barreto BC, Tantbiroj D, Versluis A, Soares CJ. Incremental filling technique and composite material--part II: shrinkage and shrinkage stresses. *Oper Dent.* 2014;39(2):E83-92.
8. Soares CJ, Faria-E-Silva AL, Rodrigues MP, Vilela ABF, Pfeifer CS, Tantbiroj D et al. Polymerization shrinkage stress of composite resins and resin cements - What do we need to know?. *Braz Oral Res.* 2017;31(suppl 1):e62.
9. van Dijken JW. A 6-year evaluation of a direct composite resin inlay/onlay system and glass ionomer cement-composite resin sandwich restorations. *Acta Odontol Scand.* 1994; 52(6):368-76.
10. Ferracane JL, Stansbury JW, Burke FJ. Self-adhesive resin cements - chemistry, properties and clinical considerations. *J Oral Rehabil.* 2011;38(4):295-314.
11. Bacelar-Sá R, Sauro S, Abuna G, Vitti R, Nikaido T, Tagami J et al. Adhesion Evaluation of Dentin Sealing, Micropermeability, and Bond Strength of

- Current HEMA-free Adhesives to Dentin. *J Adhes Dent.* 2017;19(4):357-64.
12. Alharbi A, Rocca GT, Dietschi D, Krejci I. Semidirect composite onlay with cavity sealing: a review of clinical procedures. *J Esthet Restor Dent.* 2014;26(2):97-106.
 13. Hirata R, Kabbach W, de Andrade OS, Bonfante EA, Giannini M, Coelho PG. Bulk Fill Composites: An Anatomic Sculpting Technique. *J Esthet Restor Dent.* 2015;27(6):335-43.
 14. Fron Chabouis H, Prot C, Fonteneau C, Nasr K, Chabreron O, Cazier S et al. Efficacy of composite versus ceramic inlays and onlays: study protocol for the CECOIA randomized controlled trial. *Trials.* 2013;14:278.
 15. Torres CRG, Zanatta RF, Huhtala MFRL, Borges AB. Semidirect posterior composite restorations with a flexible die technique: A case series. *J Am Dent Assoc.* 2017;148(9):671-76.
 16. Marcondes M, Souza N, Manfroi FB, Burnett LH Jr, Spohr AM. Clinical Evaluation of Indirect Composite Resin Restorations Cemented with Different Resin Cements. *J Adhes Dent.* 2016;18(1):59-67.
 17. Liu X, Fok A, Li H. Influence of restorative material and proximal cavity design on the fracture resistance of MOD inlay restoration. *Dent Mater.* 2014;30(3):327-33
 18. Fruits TJ, Knapp JA, Khajotia SS. Microleakage in the proximal walls of direct and indirect posterior resin slot restorations. *Oper Dent.* 2006;31(6):719-27.

CONFLICTS OF INTERESTS

The authors declare no conflicts of interests.

CORRESPONDING AUTHOR

Rodrigo Barros Esteves Lins

Department of Restorative Dentistry, Piracicaba Dental School, University of Campinas, Avenida Limeira, 901, Areião, Piracicaba - São Paulo, Brazil
13414-903. Tel.: +55 19 2106-5200
e-mail: rodrigowlins@hotmail.com

Received 19/08/2019

Accepted 13/04/2020