

Use of antimicrobial photodynamic therapy in the treatment of medication-related osteonecrosis of the jaw

Uso da terapia fotodinâmica antimicrobiana no tratamento da osteonecrose da mandíbula relacionada com medicamentos

Uso de terapia fotodinâmica antimicrobiana en el tratamiento de la osteonecrosis de la mandíbula relacionada con la medicación

Nizyara Costa da **SILVA**¹

Felipe Lima e **SILVA**¹

Leonardo Magalhães **CARLAN**²

Hannah Gil de Farias **MORAIS**²

Wesley Rodrigues da **SILVA**²

Maria de Lourdes Silva de Arruda **MORAIS**³

¹Universidade Potiguar – UNP. Brasil

²Universidade Federal do Rio Grande do Norte – UFRN. Brasil

³Universidade Estadual do Rio Grande do Norte – UERN / Liga Norte Riograndense Contra o Câncer - LNRCC. Brasil

Abstract

Medication-related osteonecrosis of the jaw (MRONJ) is a debilitating complication associated with antiresorptive agents, in which treatment can be quite challenging. This study aimed to report two cases of cancer patients with MRONJ treated in a complementary manner by antimicrobial photodynamic therapy (aPDT). Both patients were male, 84 and 82 years old, respectively, and had a diagnosis of prostate adenocarcinoma and bone metastasis, treated with intravenous injections of bisphosphonates. The dental history for both was toothache, followed by extraction of dental elements that culminated with the appearance of necrotic bone in the mandibular region, which was confirmed with imaging exams and histopathological reports. The treatment protocol for both cases consisted of performing the aPDT once a week, associated with the use of 10 volumes hydrogen peroxide and 0.12% chlorhexidine digluconate for continuous use after oral brushing and amoxicillin with clavulanate three times a day for 7 days. The patient in case 1 performed 27 sessions, responded well to treatment, however, due to complications of the underlying neoplasm, he died without complete resolution of the osteonecrosis. In case 2, 32 sessions were carried out, with a good evolution of the symptoms. The patient is being followed up for 14 months, with no need for surgical intervention to date. Based on the reported cases and the literature survey, it can be concluded that aPDT can be an effective alternative in cases of MRONJ. The patients in the study in question showed success and control of the clinical picture.

Descriptors: Osteonecrosis; Photochemotherapy; Diphosphonates.

Resumo

A osteonecrose dos maxilares induzida por medicamentos (OMIM) é uma complicação debilitante associada a agentes antirreabsortivos, no qual o tratamento pode ser bastante desafiador. Este estudo teve por objetivo relatar dois casos de pacientes oncológicos com OMIM tratados de maneira complementar pela terapia fotodinâmica antimicrobiana (TFA). Ambos os pacientes eram do sexo masculino, com 84 e 82 anos, respectivamente, e apresentavam diagnóstico de adenocarcinoma de próstata e metástase óssea, tratados com injeções intravenosas de bisfosfonatos. O histórico odontológico para ambos foi de odontalgia, seguida de extração dos elementos dentários que culminaram com o aparecimento de osso necrótico em região mandibular, o qual foi confirmado com exames de imagem e laudos histopatológicos. O protocolo de tratamento para ambos os casos consistiu na realização da TFA uma vez por semana, associado ao uso de água oxigenada 10 volumes e digluconato de clorexidina a 0,12% de uso contínuo após a escovação oral e amoxicilina com clavulanato três vezes ao dia durante 07 dias. O paciente do caso 01 realizou 27 sessões, respondia bem ao tratamento, entretanto, devido a complicações da neoplasia de base, veio a óbito sem resolução completa do quadro de osteonecrose. No caso 2, foram realizadas 32 sessões, com boa evolução do quadro de sintomatologia. O paciente encontra-se em acompanhamento por 14 meses, sem necessidade de intervenção cirúrgica até o momento. Com base nos casos relatados e no levantamento da literatura, pode-se concluir que a TFA pode ser uma alternativa efetiva nos casos de OMIM. Os pacientes do estudo em questão apresentaram sucesso e controle do quadro clínico.

Descritores: Osteonecrose; Fotoquimioterapia; Difosfonatos.

Resumen

La osteonecrosis de las mandíbulas inducida por fármacos (OMIM) es una complicación debilitante asociada con los agentes antirresortivos, en la que el tratamiento puede ser bastante difícil. Este estudio tuvo como objetivo informar dos casos de pacientes con cáncer con OMIM tratados de manera complementaria por la terapia fotodinámica antimicrobiana (TFA). Ambos pacientes eran varones, de 84 y 82 años, respectivamente, y tenían un diagnóstico de adenocarcinoma de próstata y metástasis óseas, tratados con inyecciones intravenosas de bifosfonatos. La historia dental de ambos fue dolor de muelas, seguido de la extracción de elementos dentales que culminaron con la aparición de hueso necrótico en la región mandibular, lo que se confirmó con exámenes de imágenes e informes histopatológicos. El protocolo de tratamiento para ambos casos consistió en realizar TFA una vez por semana, asociado con el uso de 10 volúmenes de peróxido de hidrógeno y digluconato de clorhexidina al 0,12% para uso continuo después del cepillado oral y amoxicilina con clavulanato tres veces al día. por 07 días El paciente en el caso 01 realizó 27 sesiones, respondió bien al tratamiento, sin embargo, debido a complicaciones de la neoplasia subyacente, falleció sin una resolución completa de la osteonecrosis. En el caso 2, se realizaron 32 sesiones, con una buena evolución de los síntomas. El paciente está siendo seguido durante 14 meses, sin necesidad de intervención quirúrgica hasta la fecha. Con base en los casos reportados y la encuesta de literatura, se puede concluir que TFA puede ser una alternativa efectiva en casos de OMIM. Los pacientes en el estudio en cuestión mostraron éxito y control del cuadro clínico.

Descritores: Osteonecrosis; Fotoquimioterapia; Difosfonatos.

INTRODUCTION

The medication-related osteonecrosis of the jaw (MRONJ) is the persistent exposure of the alveolar bone for more than 8 weeks in patients with a historical use of any bone

modifying agent in the absence of radiation in the head and neck areas^{1,2}. Bone modifying agents, such as bisphosphonates (Bps) and denosumab (Dmab), are widely used for the

treatment of bone reabsorbed diseases and prevention of bone metastases, however, inhibiting bone resorption, the development of osteonecrosis is predisposed²⁻⁵.

Treatment varies according to the stage of the lesion, with numerous therapeutic possibilities, such as antibacterial mouthwashes, debridement, laser therapy, hyperbaric oxygen therapy and a fibrin-rich membrane⁶. The prognosis is variable and is directly related to the presence of systemic comorbidities⁴.

The antimicrobial photodynamic therapy (aPDT) with low power red laser has been used as a promising alternative in the treatment of these diseases due to its ability to modulate metabolic, biochemical and photophysical processes, promoting analgesia processes, modulation of the inflammatory process and tissue repair⁶⁻⁸. Therefore, this study was aimed to report two cases of cancer patients with MRONJ treated in a complementary manner by aPDT.

CLINICAL CASE

o Case 1

Male patient, 84 years old, melanodermic, ex-smoker and ex-alcoholic, diagnosed with prostate adenocarcinoma and bone metastasis, underwent treatment at a reference center in oncology in the region. The treatment performed for the neoplasia was chemotherapy, using leuprorelin (Eligard®), 22.5 mg (once every 3 months), cyproterone 50mg (three times a day), associated with intravenous Pamidronate (Aredia®), which was later replaced by intravenous zoledronic acid and 250mg flutamide (three times a day) for 90 days. During cancer treatment, the patient complained of tooth pain in the region of the lower premolars on the left side, performing the extraction of these dental elements in a basic health unit in the region. Ten days after the extractions were performed, during a routine dental evaluation at the oncology center, there was an unfavorable oral hygiene and hyperemic area adjacent to the yellowish and necrotic bone exposure in the referred region of the extractions (Figure 1A). A panoramic radiography was requested, which revealed a diffuse and an irregular radiolucent image, with a format compatible with the post-extraction socket (Figure 1B). A biopsy was performed, and the specimen was sent to the pathological anatomy laboratory, reported as bone necrosis, compatible with the clinical findings. In the face of the clinical, radiographic and histopathological information, the diagnosis of osteonecrosis induced by bisphosphonate was established. As

a treatment, it was decided to perform an aPDT with a red low-power laser (MDC-Photon Laser III), 30mW power, 9J/point energy and methylene blue (MB), as photosensitizer, in the concentration of 0.01%. Before the application of MB, an irrigation with 0.09% saline was performed at the bone necrosis site (Figure 1C), using the vacuum suctioner simultaneously, to avoid recontamination of the area. Subsequently, a 0.01% MB solution was applied to the entire necrotic bone area with a disposable 3 mL syringe (Figure 1D), leaving it in contact for 5 minutes, followed by the laser application in 6 points, each with an average distance of 1 cm, 9 joules per point, and, finally, the irrigation was repeated with saline solution for another 5 minutes. The aPDT was performed once a week, which had the use of 10 volumes hydrogen peroxide and 0.12% chlorhexidine digluconate, of continued use after oral brushing, prescribed in association. In addition, it was also fixed the use of amoxicillin with clavulanate (Clavulin® 875 mg) three times a day for 07 days. The patient responded well to the treatment, however due to a collision caused by a fall, a fracture in the mandible was caused, and, after that, the lesion advanced, forming a fistula concomitant with the necrotic bone exposure, being graded as clinical stage III (Figure 1F). Twenty-seven sessions were performed until the patient was interned due to fracture and complications of the base neoplasia, without total regression. The patient died without a complete resolution of the osteonecrosis.

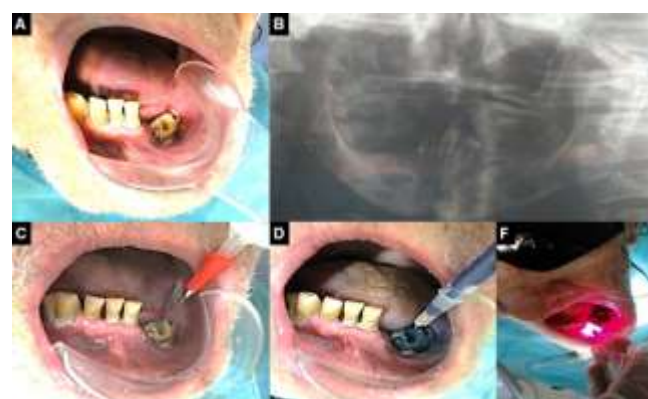

Figure 1. A) Intraoral exposure of necrotic bone in the left mandible. B) Panoramic radiography revealed a radiolucent lesion, diffuse in the mandible. C) Irrigation with 0.09% saline. D) Application of 0.01% methylene blue. E) aPDT.

o Case 2

Male patient, 83 years old, melanoderma, ex-smoker and ex-alcoholic, diagnosed with prostate adenocarcinoma and bone metastasis, also treated at the same oncology reference center in the region. It was used the same treatment as in the previous case, however,

after using Eligard, the patient used Zoladex (once a month), with a total dose of 21.6 mg. The dental history was like the first case, culminating in extraction of the dental element, which caused inconvenience, and the appearance of the necrotic bone area (Figure 2A). The panoramic radiography revealed a radiolucent area, with poorly defined contours, in the mandible on the right side (Figure 2B). Bone sequestrum was observed in the region, which was removed during biopsy and sent for histopathological analysis, reported as bone necrosis. For these characteristics, the patient was graduated as clinical stage II. The same treatment protocol of case 1, for oral hygiene recommendations and systemic antibiotic therapy (with a difference in the amount of TFA points used, 5 points now), was fixed to this patient. (Figure 2C). In the 22nd session, bone sequestrum was observed, which was referred for histopathological analysis, with the same report of bone necrosis. At the 30th session, the lesion was covered by a healthy-looking oral mucosa, but the patient still reported discomfort in the region. A new panoramic radiography was requested, in which it was possible to observe a radiolucent area in an alveolar ridge at the same location as the bone necrosis. 32 sessions were carried out, with a good evolution of the symptoms. The patient is being followed up for 14 months, with no need for surgical intervention so far (Figure 2D).

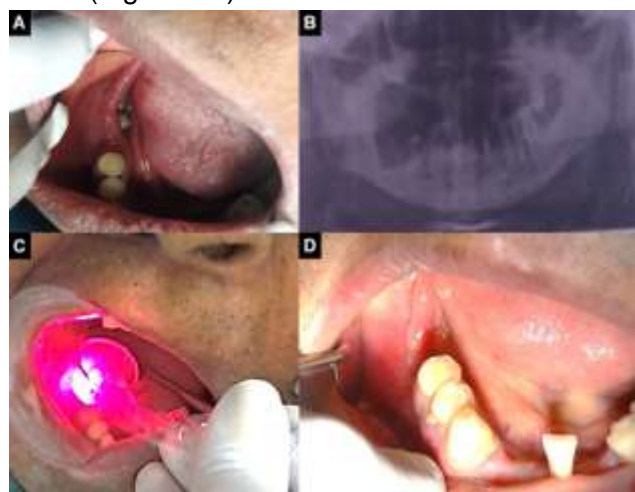


Figure 2. A) Intraoral exposure of necrotic bone in the mandible on the right side. B) Panoramic radiograph showing diffuse radiolucent lesion in the mandible. C) TFA. D) Absence of bone exposure and infection (14-month follow-up).

DISCUSSION

The Bps are analogous drugs of endogenous substances which act through two mechanisms of action related to antiosteoclastic and antiangiogenic activity, thus altering the bone tissue's mechanism at various levels and inhibiting resorption²⁻⁴.

The MRONJ's prevalence varies in

different studies, being more common in cancer patients who use or have used intravenous bisphosphonates. The mandible is more affected, due to greater bone density and less vascularization when compared to the maxilla^{3,6}. The sex predilection is quite variable, however, due to the therapeutic indication of bisphosphonates in cases of osteoporosis and breast cancer, the female sex is the most affected⁸⁻¹¹, differing from the findings of Altay et al.¹². In the present study, due to their pathology, both patients were male, and the worldwide prevalence, when compared to breast cancer, is not used as a parameter, since prostate cancer is limited to males.

The MRONJ's diagnosis is made based on medical and dental history, the use of some bone modifying agent, clinical characteristics, imaging tests^{13,14} and histopathologic analysis^{10,15}, thus it was done in the reported cases. It is worth pointing out that dental surgical procedures represent a risk factor for the MRONJ's development, with an incidence ranging from 1% to 12% in patients treated intravenously^{2,3}. Both studied patients developed MRONJ due to a dental surgical procedure, which substantiates with the current literature.

The MRONJ's treatment is extremely difficult, as the therapeutic choice must consider the general patient's health status and clinical stage of the disease⁵. The treatment strategies' principles follow the recommendations of the American Association of Oral and Maxillofacial Surgeons¹⁶, which classifies MRONJ into four clinical stages, each stage has a specific therapeutic recommendation. In stage 0 there is no need for invasive treatment, only control and prevention. In stage 1 it's recommended antibiotic treatment and regular irrigation with saline or antibiotic solution. In stage 2, in addition to drug therapy, debridement of this necrotic bone is necessary. In the last stage, in addition to drug therapies, more severe debridement or even surgical resection is recommended^{6,17,18}. Based on this classification, the patient in case 1 was classed in clinical stage III, while the patient in case 2 in stage II.

Due to the treatment's difficulty, several alternative therapeutic modalities have been suggested in recent years, including biostimulation with therapeutic laser, fibrin-rich membrane and hyperbaric oxygen therapy, which have obtained promising results. An aPDT has been proposed and highlighted among the options, since it has no side effects, it is affordable, in which a simple combination of a low energy light source (diode laser) and a photosensitizer is able to produce reactive

oxygen species and bacterial cell death^{8,19}. In addition to the antibacterial effect, the diode laser also promotes biomodulation and tissue healing^{6,17}.

The literature is scarce of studies on the use of aPDT in the treatment of MRONJ in cancer patients, having only case reports, in addition to the different protocols and lasers used in each study, being difficult to conclude about its real effectiveness. The study of Tartaroti et al.⁸ used the same protocol as in the present study, with three cancer patients in their sample who used zoledronic acid, two cases in the maxilla and one in the mandible. All had used antibiotic and aPDT treatment before debridement, with the number of sessions varying for each case (4, 5 and 9 sessions, respectively). Only one case needed to perform two aPDT sessions after debridement. All patients progressed successfully, without any complications.

A retrospective study by Altay et al.¹² evaluated and reported results of 11 cases of osteonecrosis in the mandible related to the use of Bps in stage II or III treated with low-level laser therapy, and it was observed an elimination of previously registered symptoms and the closure of the pathological wound with healthy mucosal tissue in all patients. The present study showed that only in case 2 there was control and closure of the bone wound observed during monitoring, whose only complaint was of discomfort in the region. Meanwhile, in the first case, the accident suffered during treatment and cancer activity were key factors which hindered the treatment and control of MRONJ.

The MRONJ's prognosis is related to the presence of systemic diseases, such as diabetes mellitus and malignant tumors, dosage and the medication's administration's route, interruption period, bone response factors, and size of osteolysis, being associated with therapeutic failure⁴. The patient's systemic condition, the antineoplastic treatment used and the lesion site were important factors that determined the prognosis of the present cases.

CONCLUSION

In this way, we can conclude, based on the reported cases and the literature survey, that aPDT can be an effective alternative in cases of MRONJ. The patients in the study in question evolved significantly in controlling their clinical conditions.

REFERENCES

1. Marx RE. Pamidronate (Aredia) and zoledronate (Zometa) induced avascular necrosis of the jaws: a growing epidemic. *J Oral Maxillofac Surg.* 2003;61(9):1115-17.
2. Holtmann H, Lommen J, Kübler NR, Sproll C, Rana M, Karschuck P et al. Pathogenesis of medication-related osteonecrosis of the jaw: a comparative study of in vivo and in vitro trials. *J Int Med Res.* 2018;46(10):4277-96.
3. Hasegawa T, Hayashida S, Kondo E, Takeda Y, Miyamoto, H, Kawaoka Y et al. Medication-related osteonecrosis of the jaw after tooth extraction in cancer patients: a multicenter retrospective study. *Osteoporosis Int.* 2019; 30(1):231-39.
4. Shin WJ, Chul-Hwan K. Prognostic factors for outcome of surgical treatment in medication-related osteonecrosis of the jaw. *J Korean Assoc Oral Maxillofac Surg.* 2018;44:174-81.
5. Coléte JZ, Hadad H, Momesso GAC, Santos Filho H, Fernandes BR, Garcia Junior IR. Implantes em pacientes com osteonecrose dos maxilares associado ao uso de bifosfonatos. Relato de caso e revisão de literatura. *Arch Health Invest.* 2019;8(1):20-7.
6. Weber JBB, Camilotti RS, Ponte ME. Efficacy of laser therapy in the management of bisphosphonate-related osteonecrosis of the jaw (BRONJ): a systematic review. *Lasers Med Sc.* 2016;31(6):1261-72.
7. Castro MS, Ribeiro NV, Carli ML, Pereira AAC, Sperandio FF, Hanemann JAC. Photodynamically dealing with bisphosphonate-related osteonecrosis of the jaw: Successful case reports. *Photodiagn Photodyn.* 2016;16: 72-5.
8. Tartaroti NC, Marques MM, Graça Naclério-Homem M, Migliorati CA, Zindel Deboni MC. Antimicrobial photodynamic and photobiomodulation adjuvant therapies for prevention and treatment of medication-related osteonecrosis of the jaws: case series and long-term follow-up. *Photodiagn Photodyn.* 2020;1-27.
9. Vescovi P, Merigo E, Manfredi M, Meleti M, Fornaini C, Bonanini M et al. Nd:YAG laser biostimulation of bisphosphonate-associated necrosis of the jawbone with and without surgical treatment. *Br J Oral Maxillofac Surg.* 2007;45(8):628-32.
10. Mânea HC, Urechescu HC, Balica NC, Pricop MO, Baderca F, Poenaru M et al. Bisphosphonates-induced osteonecrosis of the jaw - epidemiological, clinical and histopathological aspects. *Rom J Morphol Embryol.* 2018;59(3):825-31.
11. Atalay B, Yalcin S, Emes Y, Aktas I, Aybar B, Issever H et al. Bisphosphonate-related osteonecrosis: laser-assisted surgical treatment or conventional surgery? *Lasers Med Sci.* 2011; 26(6):815-23.
12. Altay MA, Tasar F, Tosun E, Kan B. Low-Level Laser Therapy Supported Surgical Treatment of Bisphosphonate Related Osteonecrosis of

- Jaws: A Retrospective Analysis of 11 Cases. *Photomed Laser Surg.* 2014;32(8):468-75.
13. Baba A, Goto TK, Ojiri H, Takagiwa M, Hiraga C, Okamura M et al. CT Imaging Features of Antiresorptive agent-Related Osteonecrosis of the Jaw/ Medication-Related Osteonecrosis of the Jaws. *Dentomaxillofac Rad.* 2018;47(4): 20170323.
 14. Goller-Bulut D, Özcan G, Avci F. Changes in dimension of neurovascular canals in the mandible and maxilla: A radiographic finding in patients diagnosed with MRONJ. *Med Oral Patol Oral Cir Bucal.* 2018;23(3):e282-9.
 15. Antoni CC, Matsumoto MA, Silva AA, Curi MM, Santiago Júnior JF, Sassi LM et al. Medication-related osteonecrosis of the jaw, osteoradionecrosis, and osteomyelitis: A comparative histopathological study. *Braz Oral Res.* 2018;32:e23.
 16. American Association of Oral and Maxillofacial Surgeons (AAOMS). Position paper on bisphosphonate-related osteonecrosis of the jaws. *J Oral Maxillofac Surg.* 2007;65(3): 369-76.
 17. Latifyan S, Genot MT, Klustersky J. Bisphosphonate-related osteonecrosis of the jaw: a review of the potential efficacy of low-level laser therapy. *Support Care Cancer.* 2016; 24(9):3687-693.
 18. Otto S, Pautke C, Van den Wyngaert T, Niepel D, Schiødt M. Medication-related osteonecrosis of the jaw: Prevention, diagnosis and management in patients with cancer and bone metastases. *Cancer Treat Rev.* 2018;69: 177-87.
 19. Tandon S, Lamba AK, Faraz F, Aggarwal K, Chowdhri K. A case report of Bisphosphonate Related Osteonecrosis of the Jaw treated by photodynamic therapy. *Photodiagn Photodyn.* 2019;26:313-15.

CONFLICTS OF INTERESTS

The authors declare no conflicts of interests.

CORRESPONDING AUTHOR

Maria de Lourdes Silva de Arruda Morais

Rua deputado Antônio Florêncio de Queiroz, nº 3365,
Torre Brisa do Mar - Apto 1803, Ponta Negra
Natal – RN, Brasil.

E-mail: lourd_arruda@hotmail.com

Received 25/05/2020

Accepted 23/10/2020