

Fusion or gemination? A radiologic approach

*Fusão ou geminação? Uma abordagem radiológica
¿Fusión o hermanamiento? Un abordaje radiológico*

Tamara Fernandes de CASTRO¹

Glauco Issamu MIYAHARA¹

Carla Renata Sanomiya IKUTA²

Leda Maria Pescinini SALZEDAS²

¹São Paulo State University (UNESP), School of Dentistry, Araçatuba, Oral Oncology Center, Brazil

²São Paulo State University (UNESP), School of Dentistry, Araçatuba, Department of Diagnostic and Surgery, Brazil

Abstract

A supernumerary tooth is an entity in addition to the normal series of teeth that, although rare, can be fused to a tooth, whether deciduous or permanent. Diagnosis and management in cases involving supernumerary teeth in the anterior region of the maxilla are often challenging. The clinical examination associated with the radiographic examination is decisive for the diagnosis and planning of cases. This article describes a case of unilateral fusion of a supernumerary tooth to a permanent upper lateral incisor, in which clinical and radiographic diagnosis was essential for a conservative approach.

Descriptors: Diagnosis; Fused Teeth; Tooth, Supernumerary.

Resumo

Um dente supranumerário é uma entidade adicional à série normal de dentes que, embora rara, pode se fundir a um dente, seja ele decíduo ou permanente. O diagnóstico e o tratamento em casos envolvendo dentes supranumerários na região anterior da maxila costuma ser desafiador. O exame clínico associado ao exame radiográfico é decisivo para o diagnóstico e planejamento dos casos. Este artigo descreve um caso de fusão unilateral de um dente supranumerário a um incisivo lateral superior permanente, em que o diagnóstico clínico e radiográfico foi essencial para uma abordagem conservadora.

Descritores: Diagnóstico; Dentes Fusionados; Dente Supranumerário.

Resumen

Un diente supernumerario es una entidad adicional a la serie normal de dientes que, aunque es poco común, puede fusionarse con un diente, ya sea temporal o permanente. El diagnóstico y el tratamiento en casos que involucran dientes supernumerarios en la región anterior del maxilar son a menudo un desafío. El examen clínico asociado al examen radiográfico es decisivo para el diagnóstico y planificación de los casos. Este artículo describe un caso de fusión unilateral de un diente supernumerario a un incisivo lateral superior permanente, en el que el diagnóstico clínico y radiográfico fue fundamental para un abordaje conservador.

Descritores: Diagnóstico; Dientes Fusionados; Dente Supernumerario.

INTRODUCTION

Developmental dental disorders may originate from anomalies of tooth number, size, shape, and structure. Among changes in tooth number, supernumerary teeth are the most common. Teeth are considered supernumerary when exceeds the normal series of teeth and their prevalence in the permanent dentition has been reported to be between 0.1% and 3.8%¹. The supernumerary tooth can be found in any part of the jaws, although its incidence is highest in the maxillary incisor. While fusion is considered an anomaly of shape with a prevalence of 0.5% in the permanent dentition². Fusion is the union of two dental germs that can be joined by enamel or dentin level, resulting in a single tooth², where the pulp and channels can be connected or separated based on the stage of development when the fusion occurred³. The degree of fusion depends on the stage of tooth development, the dentin joining being the main criterion⁴. These teeth are identified mainly due to their unique position and form in the dental arch. According to their position, they are termed as distomolar, mesiodens, paramolars, and mesiomolars¹. A fusion between supernumerary and permanent teeth occurs less frequently than a fusion between other types of teeth⁵. Fused teeth are found predominantly in the anterior region, and the incisors of the deciduous dentition are the most frequently affected⁶.

A common differential diagnosis for fusion is gemination but the latter causes crowding while fusion causes ectopic eruption more commonly⁷.

Mader's "two tooth" rule is a popular way of identifying the difference between fusion and gemination⁸.

The fusion of permanent and supernumerary teeth is considered unusual. Thus, the objective of this work is to report a case of fusion between a permanent tooth and a supernumerary tooth, where the knowledge of this anomaly provided a conservative treatment.

CLINICAL CASE

A 35-year-old female patient was referred to the Oral Radiology Department of the São Paulo State University (Unesp), School of Dentistry, Araçatuba, Brazil, for take panoramic radiography (Figure 1A). Clinical examination of oral structures appeared normal, except for the maxillary right (12, according to the FDI tooth numbering system), in which 12 showed a bifid crown (Figure 1 B). The patient presented no symptoms concerning the tooth aforesaid. A periapical radiograph of 12 area revealed two roots and two crowns (Figure 1 C), thus confirming the fusion with the supernumerary tooth. No treatment was prescribed since the patient reported no symptoms.

DISCUSSION

Dental fusion is the shape dental anomaly, characterized most commonly by the appearance of a clinically apparent wide tooth. Fused teeth normally appear quite unaesthetic owing to their unusual and irregular tooth morphology, mainly in the region between incisors and canines¹⁰⁻¹³, as the case described.

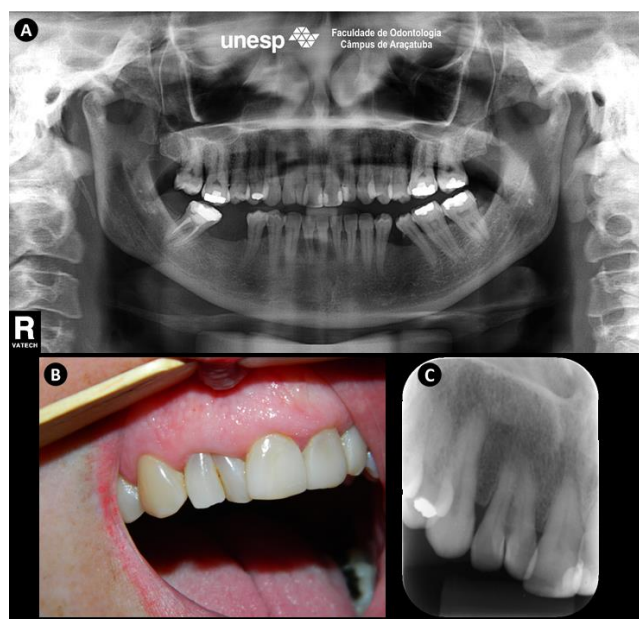


Figure 1: A) Panoramic radiography with alteration at the maxillary right (tooth12). B) Buccal view of the bifid crown; note the absence of interdental papilla. C) Periapical radiograph of the right upper lateral incisor (tooth12) with fusion of a supernumerary tooth and the tooth 12, showing two roots and two crowns.

The differential diagnosis of this condition usually lands up in confusion between fusion and gemination⁵. Gemination is a developmental anomaly of tooth shape that develops when a single tooth bud forms two teeth. It leads to the formation of two or more identical crowns, but with a single root⁹. Mader in 1979 emphasized that the teeth count in the arch is a distinguishing feature between gemination and fusion⁸, which is also known as the two-toothed rule. Mader⁸ stated that if the dental anomaly results in an extra count of the teeth number in the arch, it can be considered as gemination, whereas it can be considered as fusion if the dental anomaly results in a normal count of the number of teeth in the arch^{8,9}. Fusion is usually the cause of a reduced number of teeth in the dentition and this important fact helps to differentiate it from gemination. However, there can be exceptions, like the present case, where the fusion is seen to be occurring between a supernumerary tooth and a normal tooth.

The fusion of the teeth needs to be properly identified and a radiographic examination is an absolute prerequisite for the diagnosis and planning of these cases. Among the various radiological techniques, conventional intraoral periapical radiography is considered to be effective and effective. Conventional intraoral periapical radiography provides details of the region, low radiation dose and low cost for the patient. In the case described, it was with conventional intraoral periapical radiography that we were able to conclude the diagnosis of fusion of a permanent tooth with a supernumerary tooth.

These anomalies, if they are esthetically acceptable, require no treatment. However, they also

present a high predisposition to caries, periodontal disease, and spacing problems¹⁴. The main periodontal complication in fusion occurs due to the presence of fissures or grooves in the union between the teeth involved. Bacterial plaque accumulation in this area is quite high, which occurred in the present case. Although no aesthetic procedures were performed, the patient was oriented about proper oral hygiene and rigorous.

FINAL CONSIDERATION

Morphological and anatomical variations are not uncommon. However, its simultaneous occurrence is. Diagnosing and managing dental anomalies has always been challenging for the clinicians. This case describes the fusion between a permanent tooth and a supernumerary tooth, in the anterior region of the maxilla, from a conventional intraoral periapical radiography.

REFERENCES

1. Rajab LD and Hamdan MA. Supernumerary teeth: review of the literature and a survey of 152 cases. *Int J Paediatr Dent.* 2002;12:244-54.
2. Yang G. Supernumerary teeth and gemination. *Br J Oral Maxillofac Surg.* 2012;50:15-8.
3. Zhu M, Liu C, Ren S, Lin Z, Miao L, Sun W. Fusion of a supernumerary tooth to right mandibular second molar: a case report and literature review. *Int J Clin Exp Med.* 2015; 15;8(8):11890-95.
4. Rudagi K, Rudagi BM, Metgud S, Wagle R. Endodontic management of mandibular second molar fused to a supernumerary tooth, using spiral computed tomography as a diagnostic aid: a case report. *Case Rep Dent.* 2012;2012:614129.
5. Nandini DB, Deepak BS, Selvamani M, Puneeth HK. Diagnostic dilemma of a double tooth: a rare case report and review. *Journal of Clinical and Diagnostic Research.* 2014;8(1):271-72.
6. Duncan WK, Helpin ML. Bilateral fusion and gemination: a literature analysis and case report. *Oral Surg Oral Med Oral Pathol.* 1987; 64(1):82-7.
7. Gupta S, Singla S, Marwah N, Dutta S, Goel M. Synodontia between permanent maxillary lateral incisor and a supernumerary tooth: treatment prespective. *J Oral Health Comm Dent.* 2007;1:52-5.
8. Mader CL (1979) Fusion of teeth. *J Am Dent Assoc* 98:62-4.
9. Kumar V, Pandey V, Rohini G, Jyoti B. Fusion Between Maxillary Premolar and A Supernumerary Tooth: A Rare Case Presentation. *J Clin Diagn Res.* 2015;9(11):ZJ03-4.
10. Maréchaux SC. The treatment of fusion of a maxillary central incisor and a supernumerary: report of a case. *ASDC J Dent Child.* 1984;51:196-99.

11. De Siqueira VC, Braga TL, Martins MA, Raitz R, Martins MD. Dental fusion and dens evaginatus in the permanent dentition: literature review and clinical case report with conservative treatment. *J Dent Child (Chic)* 2004;71:69-72.
12. Karacay S, Guven G, Koymen R. Management of a fused central incisor in association with a macrodont lateral incisor: a case report. *Pediatr Dent.* 2006;28:336-40.
13. Cetinbas T, Halil S, Akcam MO, Sari S, Cetiner S. Hemisection of a fused tooth. *Oral Surg Oral Med Oral Pathol Oral Radiol Endod.* 2007;104:e120-24.
14. Nunes E, deMoraes IG, de Novaes PM, de Sousa SM. Bilateral fusion of mandibular second molars with supernumerary teeth: case report. *Brazilian Dent J.* 2002;13:137-41.

CONFLICTS OF INTERESTS

The authors declare no conflicts of interests.

CORRESPONDING AUTHOR

Leda Maria Pescinini Salzedas

Department of Diagnostic and Surgery,
São Paulo State University (UNESP)
School of Dentistry, Araçatuba, Brazil
leda.salzedas@unesp.br

Received 16/06/2020

Accepted 07/08/2020