

## Idiopathic Bone Cavity of Mandibular Symphysis: a Case Report

*Cavidade Óssea Idiopática de Sínfise Mandibular: Relato de Caso*  
*Cavidad Ósea Idiopática de la Sínfisis Mandibular: Reporte de Caso*

Department of Oral Diagnosis, Piracicaba Dental School, State University of Campinas, (FOP/UNICAMP), 13414-903 Piracicaba-SP, Brazil  
<https://orcid.org/0000-0003-0118-0958>

Department of Oral Diagnosis, Piracicaba Dental School, State University of Campinas, (FOP/UNICAMP), 13414-903 Piracicaba-SP, Brazil  
<https://orcid.org/0000-0003-2538-6299>

Department of Oral Diagnosis, Piracicaba Dental School, State University of Campinas, (FOP/UNICAMP), 13414-903 Piracicaba-SP, Brazil  
<https://orcid.org/0000-0001-7340-117X>

Department of Oral Diagnosis, Piracicaba Dental School, State University of Campinas, (FOP/UNICAMP), 13414-903 Piracicaba-SP, Brazil  
<https://orcid.org/0000-0001-6199-6276>

### Abstract

**Introduction:**An idiopathic bone cavity of the jaw is a rare pseudocyst with unclear etiology and is most commonly found in the body of the mandible. This lesion is generally asymptomatic and incidentally discovered on dental radiographs. **Objetives:**The aim of this study is to report the case of a 15-year-old male with surgical treatment of this lesion involving the mandibular symphysis, but the vitality pulp was positive. **Conclusion:** Although there is a non-surgical or surgical option for the treatment of this lesion, the latter is most indicated due to the possibility of a definitive diagnosis and improving bone repair.

**Descriptors:** Bone Cysts; Oral Pathology; Maxillofacial Pathology; Oral Surgery.

### Resumo

**Introdução:**A cavidade óssea idiopática dos maxilares é um pseudocisto raro de etiologia incerta, mais comumente encontrada no corpo mandibular. Esta lesão é, geralmente, assintomática e descoberta incidentalmente em radiografias odontológicas. **Objetivo:** relatar um caso de um jovem de 15 anos submetido à tratamento cirúrgico desta lesão em região de sínfise mandibular. Por mais que a lesão envolvia região de dentes inferiores, a vitalidade pulpar foi positiva e após a exploração cirúrgica foi confirmado o diagnóstico. **Conclusão:**Com relação ao tratamento desta lesão, existe a opção cirúrgica e a conservadora ou não cirúrgica, sendo a primeira mais indicada por possibilitar o diagnóstico adequado a partir da análise histológica.

**Descritores:** Cistos Ósseos; Patologia Oral; Patología Maxilofacial; Cirurgia Oral.

### Resumen

**Introducción:**La cavidad ósea idiopática de los maxilares es un pseudoquiste raro de etiología poco clara, que se encuentra con mayor frecuencia en el cuerpo de la mandíbula. Esta lesión es, generalmente, asintomática y se descubre incidentalmente en las radiografías dentales. **Objetivo:** Reportar un caso de cavidade óssea idiopática en mandíbula. **Informe de caso:** Un paciente masculino de 15 años de edad fue remitido con una lesión asintomática en sínfisis mandibular que involucraba dientes mandibulares anteriores, pero la pulpa de vitalidad fue positiva. **Conclusion:**Si bien existe la opción no quirúrgica y quirúrgica para el tratamiento de la lesión, esta última es la más indicada debido a la posibilidad de un diagnóstico definitivo y mejorar la reparación ósea.

**Descriptores:** Quistes Óseos; Patología Bucal; Patología Maxilofacial; Cirugía Oral.

### INTRODUCTION

An idiopathic bone cavity (IBC) is a rare benign pseudocyst of the jaw, being an intraosseous cavity without an epithelial cover, empty, or with serous or bloody fluid. The pathogenesis of the lesion is undefined; however, there is a hemorrhagic or ischemic vascular theory due to local trauma as a triggering factor<sup>1,2</sup>.

IBCs of the jaws are most commonly found in the first and second decades of life without gender predilection and mostly located in the first and second molar regions<sup>2,3</sup>. This lesion is generally asymptomatic, covered by healthy oral mucosa, and without bone expansion<sup>3</sup>.

Due to its asymptomatic features, this lesion is, in almost all cases, incidentally discovered on routine dental radiographs<sup>4</sup>. Although the teeth may be involved with the lesion, they present with positive pulp vitality<sup>5</sup>. Radiographically, this lesion demonstrates a radiolucent lesion, unilocular or multilocular

delimitation, and, in some cases, festooned extension into the teeth apices, defined as “scalloping aspect”<sup>3,6</sup>.

Although panoramic radiography may be a good diagnostic tool, computed tomography (CT) along with histologic evaluation is more proper for a definitive diagnosis<sup>5</sup>.

The treatment options include non-surgical and surgical modalities, with the former being represented by case observation and follow-up and the latter being represented by osteotomy for access associated to local curettage with or without biomaterials. The great advantage of surgical treatment is the collection of tissue for histological analysis and bone repair more quickly<sup>7,8</sup>.

The aim of this study is to report the case of a 15-year-old male who underwent surgical treatment of an IBC involving the mandibular symphysis.

### CLINICAL CASE

A 15-year-old male patient was referred to our department with an asymptomatic lesion

involving the mandibular symphysis that was incidentally discovered on a panoramic radiograph obtained by his orthodontist. The patient's medical history was otherwise irrelevant and without a history of local trauma.

On intraoral exam, the oral mucosa over the lesion was the same color and texture as the surrounding mucosa, without intra- or extraoral swelling, bone expansion or local signs of infection (Figure 1).

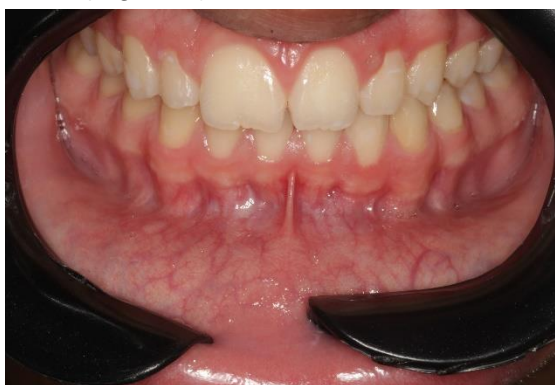

Figure 1: Intraoral view, without signs of mucosal alteration

Computed tomography (CT) was performed (Figure 2), which demonstrated a well-defined hypodense area in the mandibular symphysis (measuring about 20 mm in its largest diameter).

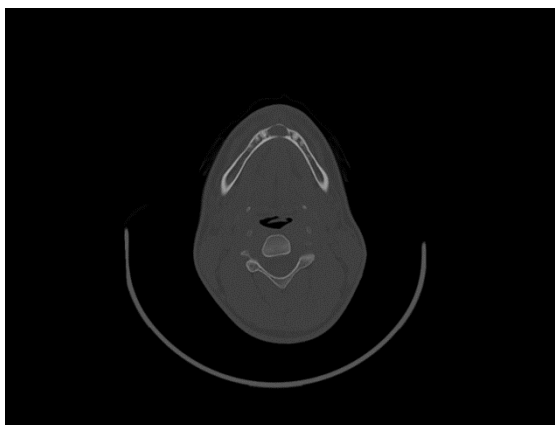


Figure 2: Well-defined hypodense area in the mandibular symphysis observed on axial view of CT.

Due to this lesion involving the teeth of the anterior mandible, pulp vitality was evaluated, which was positive. After evaluation, surgical exploration was performed under local anesthesia to obtain tissue for histological analysis, since the diagnostic hypotheses were an IBC, aneurysmal bone cyst, or giant cell central lesion.

Regarding the surgical technique, anterior mandibular vestibular access (genioplasty intraoral access) and lesion aspiration was performed, from which a distinct volume of bloody content was obtained (Figure 3).

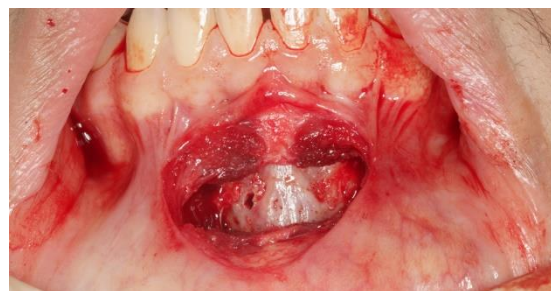


Figure 3: Intraoperative view after surgical access to lesion.

After lesion aspiration, a local osteotomy was performed on the anterior wall of the lesion for local tissue removal and curettage (Figure 4).

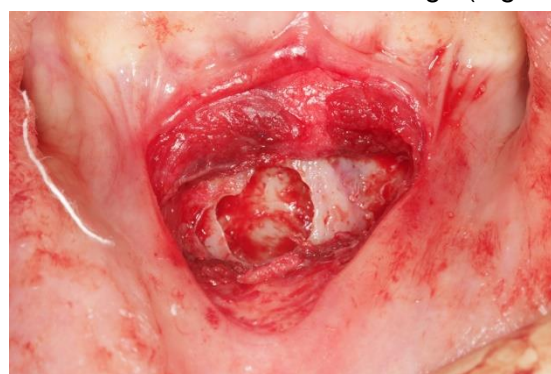


Figure 4: Intraoperative view after osteotomy and local curettage.

Finally, the bone defect was irrigated with sterile saline solution and sutured in layers with resorbable suture material.

The patient has been followed up for 4 months, with local bone in a stage of repair being observed.

## DISCUSSION

IBCs of the jaws were first reported and described in 1929 by Lucas and Blum<sup>9</sup>. Since this period, it has had several synonyms, such as simple bone cyst, traumatic bone cyst, unicameral bone cyst, solitary bone cyst, hemorrhagic bone cyst, extravasation cyst and progressive bone cyst, due the unclear pathogenesis of this lesion<sup>1-3,7</sup>. This lesion is most common in the long bones, femur, and humerus, being only 1-2% of all pseudocysts found in the jaws (with a predilection for the body of the mandible)<sup>2,4,10</sup>. The patient described presents at the age when patients are most commonly diagnosed with this lesion, although the lesion was in the midline of the mandible and not in the body, which is the most common localization in the jaw.

There is a theory that an intramedullary hematoma or ischemia caused by a traumatic event may generate local bone osteolysis, but this theory remains uncertain due to some cases in the literature without a history of associated trauma<sup>2</sup>.

The definitive diagnosis involves clinical, radiographic or tomographic, and histological analyses. An IBC is generally asymptomatic, with adjacent vital teeth and absence of bone expansion. Tomographically, it is described as a unilocular hypodense area and well circumscribed with a sclerotic margin and intact lamina dura; about 40% of these lesions show a “scalloping aspect”<sup>7</sup>. In this report, the lesion was initially viewed on a dental radiograph, but the treatment plane was defined after the CT analysis. Except for the “scalloping aspect,” all other characteristics were present in the radiological exam.

The histological analysis reveals an empty or serosanguineous cavity without an epithelial cover containing fibrous tissue associated or not with myxofibromatous proliferation. In older patients, there is a greater thickness of fibrous connective tissue than in younger patients<sup>4</sup>.

The differential diagnosis includes periapical cyst, odontogenic keratocyst, cystic ameloblastoma, dentigerous cyst, central giant cell lesion, odontogenic adenomatoid tumor, lateral periodontal cyst, ameloblastic fibroma, odontogenic myxoma, aneurysmal bone cyst, central hemangioma, and Stafne bone defect<sup>2,7</sup>.

IBCs being most common in young people, with fewer cases reported in old people, suggest that spontaneous healing may be observed. However, non-surgical treatment can be associated with the growth of the lesion. To date, there is no gold standard treatment for IBCs of the jaws, but surgical therapy by curettage is the most accepted management due to the possibility of a definitive diagnosis and improving bone repair<sup>3,7,8</sup>. Although the patient was asymptomatic, surgical exploration was performed for a proper diagnosis and due to the diagnostic hypothesis of an IBC.

The surgical technique should be more conservative with enough surgical access to perform the curettage and avoid more intense inflammatory reactions, as more aggressive access may be associated with longer repair times<sup>2</sup>. After surgical curettage, the cavity can be filled with biomaterial, such as bovine lyophilized bone, hydroxyapatite or autologous blood, despite bone repair without these biomaterials having been observed, with a mean time varying from 3 to 6 months according to the defect size<sup>2,4,8</sup>. In the present case, there was an option to perform intrasulcular access, but this would involve greater detachment of the flap and could generate some degree of gingival

recession. Therefore, a more direct surgical approach was chosen, and no biomaterial was interposed due to the size and characteristics of the bone defect, as it was a three-wall defect with the possibility of bone neoformation from a clot.

Different from this lesion in long bones, which involve a risk of pathologic fracture, the same is not associated with IBCs of the jaws<sup>1</sup>. Although IBCs of the jaws are not aggressive, their recurrence may be observed, mainly in multiple lesions with the scalloping aspect, presence of bone expansion, absence of lamina dura and associations with florid cemento-osseous dysplasia and other benign fibro-osseous lesions<sup>2,7</sup>.

IBCs of the jaws are rare and have an unclear etiology. Although there is a non-surgical and surgical option for the treatment of the lesion, the latter is most indicated due to the possibility of a definitive diagnosis and improving bone repair.

Follow-up is recommended, independent of the treatment choice, due to the possibility of recurrence in surgical cases and the possibility of enlargement of the lesion in non-surgical cases.

#### REFERENCES

1. Resnick CM, Dentino KM, Garza R, Padwa BL. A management strategy for idiopathic bone cavities of the jaws. *J Oral Maxillofac Surg.* 2016;74(6):1153-58.
2. de Lucena IM, Santos IS, Gamba TO, Flores IL, Rados PV. Recurrence of simple bone cyst: a case report and brief review of literature. *Oral Diag.* 2020;05:e20200022.
3. Battisti MPL, Soares MQS, Rubira CMF, Bullen IRFR, Lauris JRP, Damente JH. Assessment of spontaneous resolution of idiopathic bone cavity. *J Appl Oral Sci.* 2018;26:e20170288.
4. Lima LB, de Freitas Filho SA, Barbosa de Paulo LF, Servato JPS, Rosa RR, Faria PR et al. Simple bone cyst: description of 60 cases seen at a Brazilian School of Dentistry and review of international literature. *Med Oral Patol Oral Cir Bucal.* 2020(5):616-25.
5. Aoki EM, Abdala-Junior R, Nagano CP, Mendes EB, de Oliveira JX, Lourenco SV, Arita ES. Simple Bone Cyst Mimicking Stafne Bone Defect. *J Craniofac Surg.* 2018.
6. Suomalainen A, Apajalahti S, Kuhlefelt M, Hagstro J. Simple bone cyst: a radiological dilemma. *Dentomaxillofac Radiol.* 2009;38:174-77.
7. Chrcanovic BR, Gomez RS. Idiopathic bone cavity of the jaws: an updated analysis of the cases reported in the literature. *Int J Oral Maxillofac Surg.* 2019;48(7):886-94.

8. Peñarrocha-Diago M, Sanchis-Bielsa JM, Bonet-Marco J, Minguez-Sanz JM. Surgical treatment and follow-up of solitary bone cyst of the mandible: a report of seven cases. Br J Oral Maxillofac Surg. 2001;39:221-23.
9. Lucas C, Blum T: Do all cysts of the jaws originate from the dental system. J Am Dent Assoc. 1929;16:659.
10. Flores IL, Hamilton ME, Zanchin-Baldissera EdeF, Uchoa-Vasconcelos AC, Chaves-Tarquínio SB, Neutzling-Gomes AP. Simple and aneurysmal bone cyst: Aspects of jaw pseudocysts based on an experience of Brazilian pathology service during 53 years. Med Oral Patol Oral Cir Bucal. 2017;22(1):64-9.

#### CONFLICTS OF INTERESTS

---

The authors declare no conflicts of interests.

#### CORRESPONDING AUTHOR

---

**Luciano Henrique Ferreira Lima**

Department of Oral Diagnosis  
State University of Campinas,  
Piracicaba Dental School,  
Avenida Limeira, 901, Bairro Areião.  
13414-903 Piracicaba-SP, Brazil  
E-mail: luclima96@hotmail.com

**Received** 10/05/2022

**Accepted** 28/11/2022